

Phyto Effect of *Punica granatum* on the Remodelling of Maxilla Bone, Study of Osteoblast and Osteoclast

Edrizal^{1*}, Trimurni Abidin², Deddi Prima Putra³

¹Departement Doctoral Program, Dentistry Faculty, North Sumatera University Sumatera, Medan, Indonesia

²Department of Conservation, Dentistry Faculty, North Sumatera University Sumatera, Medan, Indonesia

³Pharmacy Faculty, Andalas University, Padang, Indonesia

*Corresponding author email: edrizalburhan@yahoo.com
Authors email: triabidin@yahoo.com, putra_aries64@yahoo.com,

Keywords: Punica granatum; fraction of butanol PG; remodelling of maxilla bone; osteoblast; osteoclast.

Abstract. *Punica granatum* (PG) contained anthocyanin, the chemical compound that played significant role in increasing bone cell proliferation and osteoblasts differentiation in bone remodelling. This research was aimed at measuring the effect of *Punica granatum* on maxilla bone remodelling relating to the profile of both osteoblast and osteoclast. *Punica granatum* was extracted by using butanol while the analysis of bone remodelling was conducted by observing the profile of osteoblast and osteoclast cells using histopathologic method. Butanol hydrogel of *Punica granatum* was able to enhance bone reabsorption which was proven by the increase of osteoclast and new bone formation since the osteoblast was presented. Moreover, bone remodelling activity was characterised by increased collagen fibres and osteocyte cell, in addition, bone shape compactness was getting better. Statistical analysis revealed that the histoscore profile of osteoblast was influenced by butanol fraction dosage with significance level ($p < 0.05$) which was at medium criteria according to Pearson correlation ($r = 0,6$). While the effect of dosage on osteoclast was at significance level ($p < 0.05$) but was poorly correlated with ($r = 0.01$) and osteoblast frequency was dominant at the concentration of 125 mg/ml and 250 mg/ml. On the other hand, at the concentration of 175 mg/ml osteoclast presentation was found to be more dominant. The fraction of butanol PG was able to induce osteoblast increment and osteoclast at the concentration of (mg/ml) 125, 175, and 250 and accelerate the remodelling of alveolar maxilla.

Introduction

The ethanolic extract of guava peels contains certain amount of polyphenol which stimulates the expression of angiogenesis cell in the process of new bone formation [1]. Some related researches reported that polyphenol fraction of *Punica granatum* gave significant effect on osteoblast viability. The research that used polyphenol from curcumin evidenced that the polyphenol can act as an immune stimulant for osteoblast expression in bone remodelling case [2]. The extract of *Punica granatum* peels contributes in bone remodelling by increasing osteoblast activity [3]. In addition, the extract also contained anthocyanin, a secondary metabolite that has antioxidant activity, anticancer activity and anti-inflammatory activity. Different solvent shows different quantity of polyphenol concentration, butanol extracted polyphenol from guava peel more effectively compared to other solvents like ethanol, and ethyl acetate.

Malviya reported that Pomegranate peels (*Punica granatum*) from Ganesh variety extracted using methanol showed better immune tolerant characteristic against pathogen compared to ethanolic extract, while the mixing extract of ethanol and methanol have a great antioxidant activity where polyphenol contributed as a balancing compound between antioxidant and antibacterial [4]. Furthermore, *Punica granatum* also capable of elevating cell proliferation and osteoblast

differentiation indicated by gen Runx2 expression. This assumption could be a reference to treat the osteoporosis [5]. Meanwhile, the ethanolic extract of PG leaves can also be used as anti-osteoporotic drug by inducing glucocorticoid hormone in a rabbits osteoporosis simulation [6].

Moreover, Bahtiar reported that the use of *Punica granatum* extract with the amounts of 50, 100, and 200 mg/kg can significantly prevent the bone lost which associates with increase of bone calcium as osteoblast increases [7] in the case of ovariectomy, in addition, PG can be a stimulant in preventing bone lost [3]. Based on mentioned advantages of PG in bone remodelling, therefore, this research evaluated the ability of PG to contribute in alveolar maxilla bone remodelling as a model in orthodontic treatment.

Material and Method

This research had passed ethical clearance from the Faculty of Medicine, University of North Sumatera, Medan. Indonesia No. 579 of 2016. The research material was pomegranate fresh (*Punica granatum*) of 20 kg collected from North Sumatra. Medan. At the initial stage of the research extraction and fractionation of *Punica granatum* (PG) rind was carried out at the Biota and Pharmacy Laborabbitsory, Faculty of Pharmacy, Andalas University, West Sumatera, a certificate of completion of the research No.14/ UN16.26 / TU / 2019, to measure maxilla bone remodelling based on the profile of osteoclast and osteoblast. The modelling was conducted in-vivo involving modelled rabbit which then undergo euthanasia and the osteoblast and osteoclast profiles of maxilla bone were examined using histopathological method at Biological Laborabbitsory Faculty of Mathematics and Natural Science, University of North Sumatera, Medan, Indonesia.

Pomegranate rind (*Punica granatum*) was cut into small pieces and dried at 30-40°C. Dry samples were mashed, weighed and macerabbitised with 96% ethanol (1:10) 9 L for 24 hours, occasionally stirring in the first 6 hours. On the second day the macerabbitise was filtered (Maserabbit I), the dregs was continued macerabbitision to II with 96% ethanol (1: 5) 4.5 L for 24 hours. On the third day, Maserabbit II was filtered and combined with Maserabbit I. Steam the solvent to obtain a thick extract of 164.4 grams.

The next step was the fractionation process using non-polar solvents (n-hexane), semi-polar solvents (ethyl acetate) and polar solvents (butanol). Fractionation could be carried out by the liquid extraction method by using a separabbitising funnel to separabbitise compounds that were soluble in hexane, ethyl acetate and butanol with water. Each fraction was solvent evaporabbitised *in vacuo* by using a rotary evaporabbitisor at 40°C. Furthermore, the determination of total phenolic content in each fraction of pomegranate rind extract (*Punica granatum*) was carried out by the method *Folin Ciocalteu* in order to measure total phenolic compounds in test sample [8]. Calculate the total polyphenol content in each fraction of pomegranate rind extract (*Punica granatum*) using gallic acid standards to get the equivalent gallic acid/ gram extract or fraction.

The highest polyphenol content was determined by the butanol fraction 157.52 mg/g gallic acid equivalence, hexane fraction 13.81 mg/ g gallic acid equivalence and ethyl acetate fraction 155.81 mg/ g gallic acid equivalence. Butanol fraction containing the most total phenol 157.52 mg/ g gallic acid equivalence, meaning that butanol fraction had considerable antioxidant activity that was taken for use as a test material formulated into hydrogel with a concentrabbitision of 125 mg/ ml, 175 mg/ ml and 250 mg/ ml to measure maxillary bone remodeling based on osteoblast and osteoclast profiles. In-vivo modeling using rabbits New Zealand White aged 6-8 weeks, body weight from 1.8 to 2.2 kg and male sex with 24 tails divided into four groups. Each rabbit from each group was given the treatment of fixed orthodontic device attachment to the upper incisors using open coil spring to move the teeth. Before the installation of fixed orthodontic devices the rabbit was anesthetized with ketamine (ketamine dose 35 mg/ kg BW) intramuscularly on the gluteus muscle. After 15 days of movement in the teeth marked by incisor space between the teeth, the coil spring was removed then *Punica granatum* hydrogel was applied to the tooth area which occurs through subgingival concentrabbitision of 125 mg/ ml, 175 mg/ ml and 250 mg/ ml for 15 days except the control group. The euthanasia of the rabbits were then performed, subsequently, the rabbits were dissected in order to obtain maxilla bones [9]. The first step was that body parts from head to the neck was immersed

in the solution of *neutral buffered formaldehyde* 10%, then histopathologic preparabbitsion was conducted starting with organ *trimming* where the bones were cut off in to 1 cm x 1 cm x 1 cm sizes, decalcified followed by dehydrabbitsing twice in acetone for 1.5 hours, then *clearing* process was carried out by saturabbitsing the brains in *xylol* solution twice for 1.5 hours.

The procedure was then continued to paraffin infiltrabbitsion process by soaking the organ in to the liquid paraffin twice for 1.5 hours which were carried out in a heating oven at the temperabbitsure of 60°C. Finally, *embedding/blocking* the tissue was performed by embedding the brains in the paraffin blocks, the blocks were then left to freeze and then sliced in to 5 µm by using *microtomic rotary*. The sliced tissue spread out in water at temperabbitsure 50°C, then was taped on to an *object glass* which have been previously applied with Mayers *albumin*, subsequently dried on a *hot plate* for approximately ±2 minutes and left to dry at room temperabbitsure for 24 hours.

The next stage was colouring with *hematxylin-eosin* by soaking the tissue in *xylol*, then in the absolute alcohol, in alcohol 96%, alcohol 90% and lastly in water (each treatment was conducted twice for 2 minutes each). The tissue was then soaked in *hematoxylin* and then was rinsed with aquadest until clear tissue obtained. The tissue was then soaked in acidic alcohol twice, 3 times in aquadest, *eosin* for about 1-2 minutes and finally dipped in to water 3 times. The soaking was then continued in alcohol 96% twice for 1 minute each, absolute alcohol twice for 1 minute and twice in *xylol* for 2 minutes each time. The final process was covering the tissue with Canadian balm and was left out to let the adhesive dried (± 12 hours) then the preparabbitse was ready to be observed under the microscope. The observation was carried out to investigate the histopathologic profile of osteoblast, osteoclast, osteocyte, and the collagen fibre using 1000x microscope.

Results

Figure 1 shows that butanol hydrogel of *Punica granatum* was capable of increasing bone reabsorption indicated by osteoclast increment and new bone formation with the presence of osteoblasts. Whereas Figure 2 depicted the maxilla bone remodelling activity after administrabbitsion of butanol hydrogel of *Punica granatum*, the increase of both collagen fibres and osteocyte cells is key indicators for bone remodelling activity. Additionally, the activity of bone remodelling also confirmed by better bone compactness. Table 1 illustrabbitsed that histoscore values of osteoblast and osteoclast was dictated by the dosage of butanol fraction with significance level ($p < 0.05$), and medium Pearson correlation ($r = 0.6$). While the dosage effect on osteoclast cell was at significance level ($p < 0.05$) but with weaker correlation ($r = 0.01$). Furthermore, the table also revealed that osteoblast frequency was dominant at the concentrabbitsion of 125 mg/ml and 250 mg/ml. While the concentrabbitsion of 175 mg/ml shows that the osteoclast percentage was dominant.

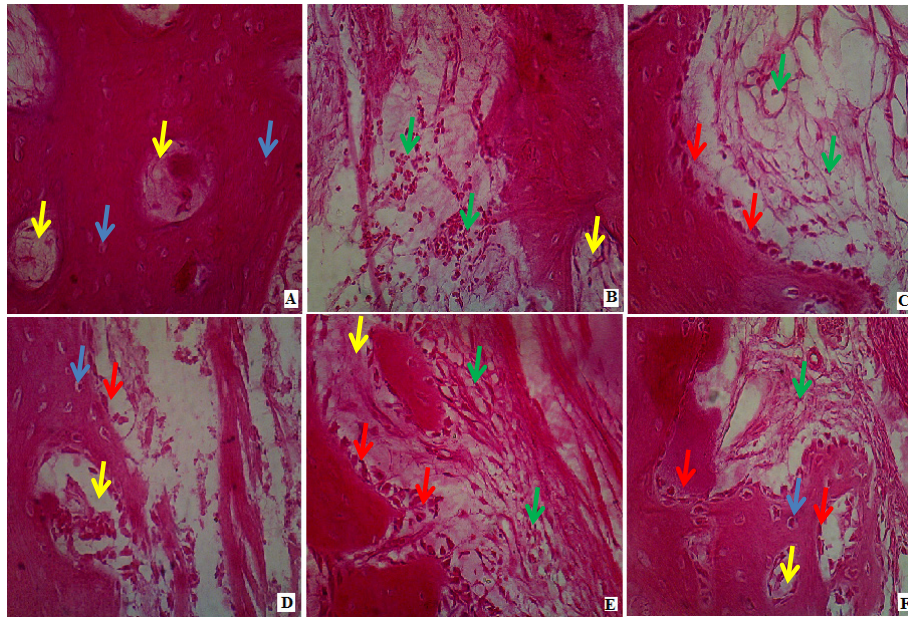


Figure 1. Profiles of osteoblast and osteoclast cells in the process of maxilla bone remodelling. Blue arrows (osteocyte cells); yellow arrows (lamella); green arrows (osteoblast); red arrows (osteoclast). (A) Negative control without treatment (B) Positive control with ortho wire treatment, without *Punica granatum* hydrogel. (C). Concentration of 125 mg/ml, (D). Concentration of 175 mg/ml, and (E & F) Concentration of 250 mg/ml. 40 x magnifications, electron microscope coupled with OpticViewer 2017.

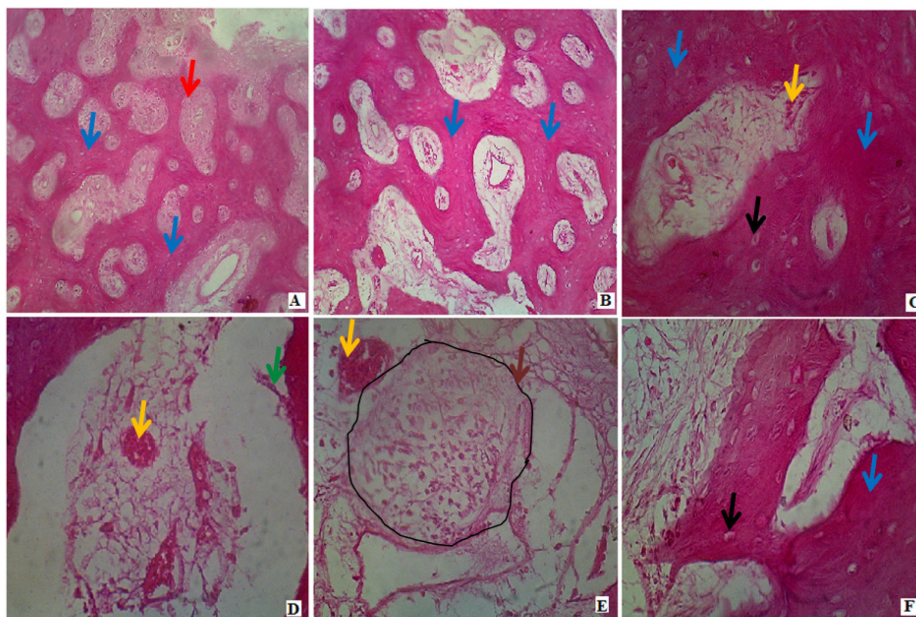


Figure 2. Maxilla bone remodelling profile. Blue arrows (bone matrix); yellow arrows (Veins); green arrows (osteoclast); red arrows (lamella) black arrows (osteocyte), brown arrows (osteoblast). 40x magnification, electron microscope coupled by optic viewer 2017.

Table 1. Histoscore profile of osteoblast and osteoclast alveolar maxilla bone

| Dosage | Osteoblast | | | | | Osteoclast | | | | |
|---------|-------------------|-------|---------------|----------|----------|-------------------|-------|---------------|----------|----------|
| | Histoscore (cell) | SDV | Frequency (%) | <i>p</i> | <i>r</i> | Histoscore (cell) | SDV | Frequency (%) | <i>p</i> | <i>r</i> |
| Control | 54,4 | 1,930 | 30% | | | 6 | 0,242 | 27% | | |
| 125 | 57,6 | 3,243 | 33% | (p<0,05) | 0,6 | 8 | 0,707 | 29% | p<0,05 | 0,01 |
| 175 | 56,6 | 0,833 | 32% | | | 11,8 | 1,924 | 42% | | |
| 250 | 61,4 | 2,415 | 55% | | | 8 | 0,707 | 29% | | |

Discussion

The research findings reveal that the extract of *punica granatum* (PG) was able to increase the deposit of bone organo-matrix like osteoblast, osteoclast, and collagen fibre (Figures 2). PG also has strong properties on collagen expression, which indicates that ascorbic acid capability to stimulate the formation of collagen matrix including the expression of *hydroxylation proline* gen and lysine in collagen during post-translational modification [10]. Meanwhile, this research shows that PG was highly sensitive to the expression of BMP-2 [11].

New bone formation was facilitated by certain bone marker proteins such as *bone alkaline phosphatase*, *osteocalcin*, and *pro-collagen type I C terminal peptide*. Whereas, bone reabsorption activity also facilitated by bone marking proteins like *hydroxyproline*, *pyridinoline*, *desoxypyridinoline* and *Ntx* [12]. The number of bone marking proteins initiate the formation of new bone, where collagen fibre play important role in bone proliferating activity as part of new bone remodelling. Osteoblast and osteoclast are two indicative cells of new bone rehabilitation [13]. In remodelling process, the bone is filled by certain granulated tissues such as capillary, fibroblast and progenitor resulting the osteoblast [14]. Figures 1 illustrates that butanol hydrogel of *Punica granatum* was capable of increasing bone absorption indicated by formation of osteoclast and the formation of new bone was observed as osteoblast presence.

The bone tissue then help the remodelling process through collaboration with bone cell including osteoclast reabsorption and new bone formation by osteoblast [15]. The process occurred under the control of development factor and cytokine which systemically influenced by calcitonin and oestrogens, these factors contributed to bone balance [15]. The imbalance between formation and reabsorption of bone lead to osteoporosis disease [16]. Recently, bone remodelling is commonly known as communication among bone cells [17]. For instance, reabsorption activity and bone formation occur due to interaction between osteoblast and osteoclast. Furthermore, osteocyte generates factors that affect the activity of both osteoblast and osteoclast [18]. The phenomenon illustrates the complete communication between bone cells and other tissues, and naturally identified that the structure and function of bone cells affected the bone remodelling [19]. Figures 2 depicted remodelling activity of maxilla after being applied by *Punica granatum* butanol hydrogel, the remodelling activity was associated with collagen fibre formation, osteocyte cell, and better bone compactness.

Histopathological, PG provided significant impact on increasing osteoclast and osteoblast. The balanced communication between the two cells indicated that PG was capable of balancing and modulating the bone remodelling process (Table 1). The effects of PG on bone remediation histologically studied by Tore, the extract of PG was associated with the formation of collagen containing osteoblast and significantly prevent the osteoporosis [20]. Another study reported that the preparation of maxillary bone repair with eosin and haematoxylin staining (HE) showed the expression of fibroblast growth factor (FGF-2) and alkaline phosphatase (ALP) in the

process of bone healing, which Immunohistochemistry between FGF-2 and ALP was very strong after preparabbitsion with PG. Likewise the role of polyphenols PG can inhibit bone resorption by blocking osteoclast mRNA gene expression such as MMP-9, cathepsin-K, calmodulin, CC chemokine receptor type 2 (CCR2), calcitonin receptor and TRAP through down regulation of NF- κ B [3,21,22].

The use of different PG concentrabbitsions (10-100 μ g/ml) against osteoblastic cells showed characteristic morphological changes, significantly showing the proliferabbitsion of collagen fibers of matrix mineralization of osteoblasts ($p < 0.05$), this suggests that PG can have an effect to stimulate formation osteoblastic bones that have the potential to prevent osteoporosis. Table 1 shows the histoscore value of osteoblasts and osteoclasts significantly increased between dosage administrabbitsion, where histoscore profile of osteoblasts was affected by significant dosage of butanol fraction ($p < 0.05$) with moderabbitse Pearson correlation ($r = 0.6$). While the effect of dosage on osteoclast cells was significant ($p < 0.05$) but the strength of the relationship was very weak ($r = 0.01$).

Figures 2 shows the action of maxillary bone remodelling after orthodontic wire was prepared in experimental animals, in the picture the expression of osteoblasts and osteoclasts was equilibrium. Bone repair activities are always influenced by bone balance which is a balance between osteoclast and bone formation by osteoblasts. Osteoblasts not only synthesize bone protein matrices but regulate bone maturabbitsion by soluble factors and their interactions [23]. Ripening of the osteoclast requires stimulation of RANKL expressed by osteoblasts while the interaction is mediated by firm adhesion via ICAM-1 [24]. During the process, pro-inflammation such as cytokines IL-1 and TNF-alpha can cause imbalance of bone resorption in osteoblasts [25]. Inflammatory signals originate from the immune system as a source of transmission through an osteoblast response which induces osteoclast maturabbitsion [26]. As reported in Table 1, where the osteoblast frequency is dominant at concentrabbitsions of 125 mg/ml and 250 mg/ml. While the concentrabbitsion of 175 mg/ml showed the percentage of osteoclasts was more dominant.

Conclusion

The conclusion of this study was that *Punica granatum* has an effect on alveolar bone remodelling after orthodontic tooth movement characterized by an increase in osteoblast frequency at concentrabbitsions of 125 mg/ml and 250 mg/ml and at 175 mg/ml has an effect on increasing osteoclast.

References

- [1] Turrini E, Ferruzzi L, and Fimognari C. Potential effects of pomegranate polyphenols in cancer prevention and therapy. *Oxid Med Cell Longev*, 2015
- [2] López-Lázaro M. Anticancer and carcinogenic properties of curcumin: considerabbitsions for its clinical development as a cancer chemopreventive and chemotherapeutic agent. *Mol Nutr Food Res*, 52(S1), S103-S127, 2008
- [3] Spilmont M, Léotoing L, Davicco MJ, Lebecque P, Miot-Noirault E, Pilet P, Coxam V. Pomegranate peel extract prevents bone loss in a preclinical model of osteoporosis and stimulates osteoblastic differentiation in vitro. *Nutrients*, 7(11), 9265-9284, 2015
- [4] Malviya S, Arvind Jha A, and Hettiarachchy N. Antioxidant and antibacterial potential of pomegranate peel extracts. *J Food Sci Technol*, 51(12), 4132-4137, 2014
- [5] Siddiqui S, and Arshad M. Osteogenic potential of punica granatum through matrix mineralization, cell cycle progression and runx2 gene expression in primary rabbits osteoblasts. *DARU*, 22(1), 72, 2014

-
- [6] Banu J, Varela E, and Fernandes G. Alternative therapies for the prevention and treatment of osteoporosis. *Nutr Rev*, 70(1), 22-40, 2012
- [7] Bahtiar A, Arifin S, Razalifha A, Qomariah N, Wuyung P, and Arsianti A. Polar fraction of *Punica granatum* L. Peel extract increased osteoblast number on ovariectomized rabbits bone. *Int. J. Herbal Med*, 2, 65-70, 2014
- [8] Chun, O.K., Kim, D.O., and Lee, C, Y. Superoxide Radical Scavenging Activity of The Major Polyphenols in Fresh Plums. *J Agric Food Chem*. 2003.
- [9] Rentsch C, Schneiders W, Manthey S, Rentsch B, and Rammelt S. Comprehensive histological evaluation of bone implants. *Biomatter*, 4(1), e27993, 2014
- [10] Franceschi RT, Iyer BS, and Cui Y. Effects of ascorbic acid on collagen matrix formation and osteoblast differentiation in murine MC3T3-E1 cells. *Journal of bone and mineral research*. 9(6), 843-854, 1994
- [11] Edrizal B, Bergman T, Trimurni A, Deddi Prima P, and Basri, AG. Analysis reactivity of *Punica Granatum* polyphenols to the osteocalcin, bone morphogenetic protein, and collagen type 1. *Asian Journal of Pharmaceutical and Clinical Research*, 11 (12). doi:10.22159/ajpcr.2018.v11i12.29683, 2018
- [12] Pereira JV, Modesto-Filho J, de FAgra M, and Barbosa-Filho JM. Plant and plant-derived compounds employed in prevention of the osteoporosis. *Acta Farmaceutica Bonaerense* 21(3), 223-234, 2002
- [13] Martin RB, Burr DB, Sharkey NA, and Fyhrie DP. Growth, modeling and remodeling of bone *skeletal tissue mechanics* (pp. 95-173): Springer, 2015
- [14] Hwang J. *Integrabbitson of cartilage and bone through a calcified cartilage interface to form a functional osteochondral graft*: University of California, San Diego, 2010
- [15] Florencio-Silva R, Sasso GR dS, Sasso-Cerri E, Simões MJ, and Cerri PS. Biology of bone tissue: structure, function, and factors that influence bone cells. *BioMed Research International*, 2015
- [16] Kini U, and Nandeesh B. Physiology of bone formation, remodeling, and metabolism *Radionuclide and hybrid bone imaging* (pp. 29-57): Springer. 2012
- [17] Martin T, and Ng K. Mechanisms by which cells of the osteoblast lineage control osteoclast formation and activity. *J Cell Biochem*, 56(3), 357-366, 1994
- [18] Schindeler A, McDonald MM, Bokko P, and Little DG. *Bone remodeling during fracture repair: the cellular picture*. Paper presented at the Semin Cell Dev Biol, 2008
- [19] Florencio-Silva R, Sasso GR dS, Sasso-Cerri E, Simões MJ, and Cerri PS. Biology of Bone Tissue: Structure, Function, and Factors That Influence Bone Cells. *BioMed Research International*. 421746. doi:10.1155/2015/421746, 2015
- [20] Torre E. Molecular signaling mechanisms behind polyphenol-induced bone anabolism. *Phytochemistry Reviews*, 16(6), 1183-1226, 2017
- [21] Hsu YC, Cheng CP, and Chang DM. *Plectranthus amboinicus* attenuates inflammatory bone erosion in mice with collagen-induced arthritis by downregulation of RANKL-induced NFATc1 expression. *The Journal of rheumatology*, 38(9), 1844-1857, 2011
- [22] Santiago-Mora R, Casado-Diaz A, De Castro M, and Quesada-Gomez J. Oleuropein enhances osteoblastogenesis and inhibits adipogenesis: the effect on differentiation in stem cells derived from bone marrow. *Osteoporosis international*, 22(2), 675-684, 2011
- [23] Tanaka Y, Nakayamada S, and Okada Y. Osteoblasts and osteoclasts in bone remodeling and inflammation. *Current Drug Targets-Inflammation & Allergy*, 4(3), 325-328, 2005

-
- [24] Grzibovskis M, Pilmane M, and Urtane I. Today's understanding about bone aging. *Stomatologija*, 12(4), 99-104, 2010
- [25] Livshits G. Quantitative genetics of circulating molecules associated with bone metabolism: a review. *Journal of Musculoskeletal And Neuronal Interactions*, 6(1), 47, 2006
- [26] Walsh MC, and Choi Y. Biology of the RANKL–RANK–OPG system in immunity, bone, and beyond. *Frontiers in Immunology*, 5, 511, 2014